

TELEDERMATOLOGY TRAINING FOR RESIDENTS USING A CASE-BASED TELEMEDICINE PLATFORM

Lainee Goettsche, BS

Lulit Price, MD

Pooja Chitgopeker, MBChB

Karolyn Wanat, MD



BACKGROUND

- It is becoming more important for future dermatologists to be educated on its benefits and limitations
- Currently, formal training in teledermatology during residency is limited¹
- Prior data has suggested that interactive learning sessions improve knowledge retention²

1. Wanat KA, Newman S, Finney KM, Kovarik CL, Lee I. Teledermatology Education: Current Use of Teledermatology in US Residency Programs. *J Grad Med Educ.* 2016 May;8(2):286-7.

2. Horne A, Rosdahl J. Teaching Clinical Ophthalmology: Medical Student Feedback on Team Case-Based Versus Lecture Format. *J Surg Educ.* 2016 Sept; (16)30140-4.

PURPOSE

To introduce teledermatology to residents via an interactive case-based application that demonstrates the advantages and limitations of this type of care and to eventually expand to enhance the medical student curriculum

METHODS

Pre-survey

- 15 residents pertaining to prior experiences of teledermatology

Cases and Platform

- 10 cases varying difficulty and image quality developed in a home-grown platform

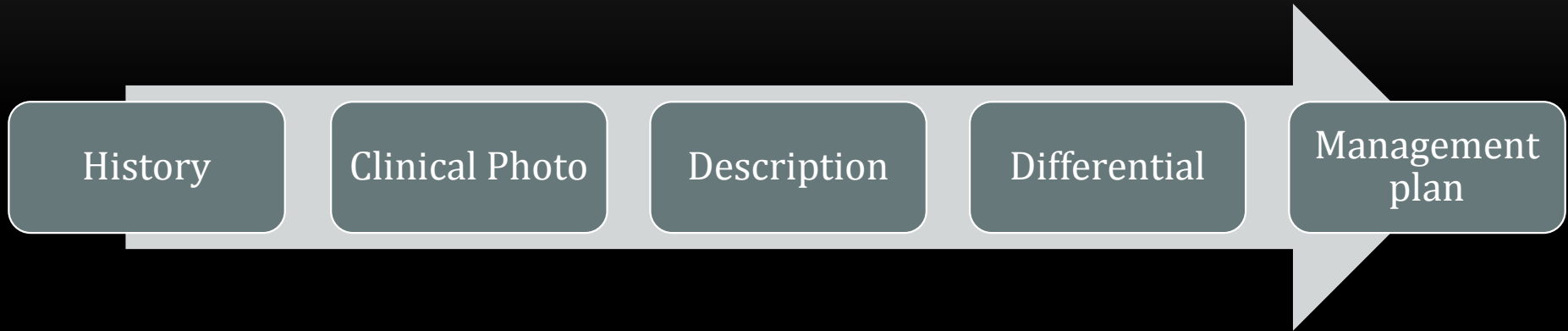Review Session

- Lead by dermatology faculty with a focus on the most difficult topics

Post-survey

- 15 residents pertaining to experience and opinion of the application

CASE FLOW



CASE FLOW

History

Clinical Photo

Description

Differential

Management
plan

Eosinophilis granulomatosis
with polyangitis

Acquired ichthyosis

Photocontact dermatitis

Seborrheic dermatitis

Neutrophilic dermatosis of
dorsal hands

Guttate psoriasis 2/2 Strep

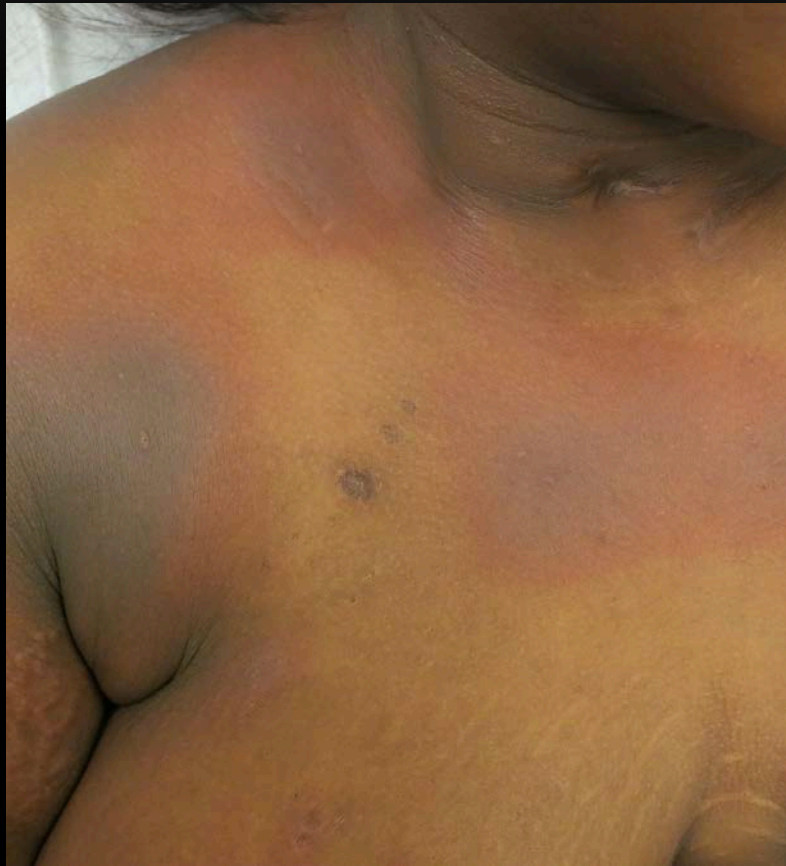Melanoma

Seborrheic keratosis

Fixed drug eruption

Urticaria

EXAMPLE PHOTOS



RESULTS

	Pre-survey	Post-survey
Ability to give a differential diagnosis via photo alone	2.7	4.0
Ability to give one best diagnosis via photo alone	2.3	2.8
Teledermatology exposure during residency would increase dermatology knowledge	3.7	4.0
Application provides opportunity to improve diagnosis and management skills	3.9	3.9
Application would be a valuable addition to curriculum to enhance teledermatology skills	3.6	3.7

*Likert scale data

RESULTS

	Pre-survey	Post-survey
Ability to give a differential diagnosis via photo alone	2.7	4.0
Ability to give one best diagnosis via photo alone	2.3	2.8
Teledermatology exposure during residency would increase dermatology knowledge	3.7	4.0
Application provides opportunity to improve diagnosis and management skills	3.9	3.9
Application would be a valuable addition to curriculum to enhance teledermatology skills	3.6	3.7

*Likert scale data

RESULTS

	Pre-survey	Post-survey
Ability to give a differential diagnosis via photo alone	2.7	4.0
Ability to give a differential diagnosis via photo and history	3.3	3.9
Teledermatology exposure during residency would increase dermatology knowledge	3.7	4.0
Application provides opportunity to improve diagnosis and management skills	3.7	3.9
Application would be a valuable addition to curriculum to enhance teledermatology skills	3.6	3.7

*Likert scale data

RESULTS

	Pre-survey	Post-survey
Ability to give a differential diagnosis via photo alone	2.7	4.0
Ability to give one best diagnosis via photo alone	2.3	2.8
Teledermatology exposure during residency would increase	3.7	4.0
Application provides opportunity to improve diagnosis and management skills	3.9	3.9
Application would be a valuable addition to curriculum to enhance teledermatology skills	3.6	3.7

*Likert scale data

RESULTS

- 13 of 15 residents did not have prior experience with teledermatology
 - Preference for 2-5 cases or a 'case-of-the-week' model
 - Current platform left much to be desired
-

CONCLUSIONS

- The addition of formal telemedicine education to the curriculum is valuable for resident learning and increases exposure to the nuances of teledermatology
 - This web-based application is a successful means to introduce the concept of teledermatology to residents
 - Case-based learning could be a supplement to the upcoming AAD teledermatology curriculum
-

PLANS

Platform

Residency
training

Medical
student
training

NEW PLATFORM MEDICAL STUDENT CASE



Case 2

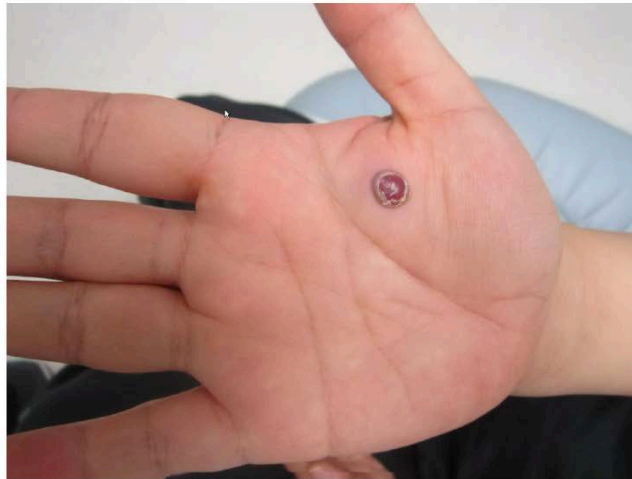
A 27-year-old pregnant female presents with a new growth on her hand. She says it started as a small red spot about the size of a pin and has continued to grow. It is painless but bleeds frequently. She is not taking any medications besides a daily multivitamin. **Any thoughts on diagnosis?**



NEW PLATFORM MEDICAL STUDENT CASE



Case 2



Describe what you see.

Provide a differential diagnosis.

Suggest a treatment plan.

NEW PLATFORM

MEDICAL STUDENT CASE



Case 2

Describe what you see.

Expert answer

Deep red, dome-shaped, shiny papule with a collarette of scale on the palm.

Your answer

Provide a differential diagnosis.

Expert answer

pyogenic granuloma, hemangioma, poroma, clear cell acanthoma, amelanotic melanoma

Your answer

Suggest a treatment plan.

Expert answer

shave removal with electrodesiccation of the base, avoid trauma, discontinue inciting medications if any

Your answer

HawkID



THANK YOU
